

ZEISS PLEX Elite 9000 Widefield Optical Coherence Tomography Angiography as Screening Method for Early Detection of Retinal Hemangioblastomas in von Hippel–Lindau Disease

Stefan J. Lang^{1,2}, Michelle Dreesbach¹, Yannik Laich¹, Andreas Glatz¹, Daniel Boehringer¹, Viviane Grewing¹, Marianne Fritz¹, Felicitas Bucher¹, Wolf A. Lagrèze¹, Peter M. Maloca^{3,4}, Thomas Reinhard¹, Clemens Lange¹, Hansjuergen Agostini¹, and Michael Reich¹

¹ Eye Center, Medical Center–University of Freiburg, Faculty of Medicine, University of Freiburg, Freiburg, Germany

² Department of Ophthalmology, University Hospital Brandenburg, Brandenburg Medical School Theodor Fontane (MHB), Brandenburg an der Havel, Germany

³ Institute of Molecular and Clinical Ophthalmology Basel (IOB), Basel, Switzerland

⁴ Moorfields Eye Hospital NHS Foundation Trust, London, UK

Correspondence: Michael Reich, Eye Center, Medical Center–University of Freiburg, Faculty of Medicine, University of Freiburg, Killianstrasse 5, Freiburg D-79106, Germany. e-mail: drmichaelreich@web.de

Received: November 27, 2023

Accepted: January 3, 2024

Published: February 12, 2024

Keywords: von Hippel–Lindau; retinal hemangioblastoma; optical coherence tomography angiography; screening; ophthalmoscopy

Citation: Lang SJ, Dreesbach M, Laich Y, Glatz A, Boehringer D, Grewing V, Fritz M, Bucher F, Lagrèze WA, Maloca PM, Reinhard T, Lange C, Agostini H, Reich M. ZEISS PLEX elite 9000 widefield optical coherence tomography angiography as screening method for early detection of retinal hemangioblastomas in von Hippel–Lindau disease. *Transl Vis Sci Technol.* 2024;13(2):8. <https://doi.org/10.1167/tvst.13.2.8>

Purpose: To evaluate early detection of retinal hemangioblastomas (RHs) in von Hippel–Lindau disease (VHLD) with widefield optical coherence tomography angiography (wOCTA) compared to the standard of care in ophthalmologic VHLD screening in a routine clinical setting.

Methods: We conducted prospective comparisons of three screening methods: wOCTA, standard ophthalmoscopy, and fluorescein angiography (FA), which was performed only in uncertain cases. The numbers of detected RHs were compared among the three screening methods. The underlying causes for the lack of detection were investigated.

Results: In 91 eyes (48 patients), 67 RHs were observed (mean, 0.74 ± 1.59 RH per eye). FA was performed in eight eyes. Ophthalmoscopy overlooked 25 of the 35 RHs detected by wOCTA (71.4%) due to the background color of the choroid ($n = 5$), small tumor size ($n = 13$), masking by a bright fundus reflex ($n = 2$), and masking by surrounding retinal scars ($n = 5$). However, wOCTA missed 29 RHs due to peripheral location (43.3%). The overall detection rates were up to 37% on the basis of ophthalmoscopy alone, up to 52% for wOCTA, and 89% for FA. Within the retinal area covered by wOCTA, the detection rates were up to 46.7% for ophthalmoscopy alone, up to 92.1% for wOCTA, and 73.3% for FA.

Conclusions: The overall low detection rate of RHs using wOCTA is almost exclusively caused by its inability to visualize the entire peripheral retina. Therefore, in unclear cases, FA is necessary after ophthalmoscopy.

Translational Relevance: Within the imageable retinal area, wOCTA shows a high detection rate of RHs and therefore may be suitable to improve screening for RHs in VHLD.

Introduction

von Hippel–Lindau disease (VHL) is an autosomal-dominant inherited phacomatosis¹ with a predisposition for multifocal tumors such as neuroendocrine tumors in the pancreas and adrenal gland, renal carcinomas, and hemangioblastomas in the central nervous system and retina.^{2–4} Retinal hemangioblastomas (RHs) are a common ocular manifestation in VHL. A prevalence of up to 79% has been reported.⁵ Average age of onset for RHs is between 25 and 30 years^{6–8}; nevertheless, RHs have also been described in childhood.⁹ RHs are benign tumors that usually consist of proliferations of endothelial and glial cells.¹⁰ However, despite their benign nature, loss of vision and even blindness can be caused by RHs due to associated subretinal fluid and exudative or tractional retinal detachment.¹¹ Because RHs can occur at any age and usually in early stages do not cause any symptoms, life-long screening for RHs is necessary.¹² This screening has to be repeated regularly and includes a thorough examination of the whole retina.^{12,13} Fluorescein angiography (FA) shows a higher detection rate of RHs than clinical examination.¹⁴ However, due to the dye injection, FA is an invasive, time-consuming procedure that poses risks for the patient.¹⁵ Treatment options for peripheral RHs include laser photocoagulation, cryotherapy, brachytherapy, transpupillary thermotherapy, and intravitreal injection of vascular endothelial growth factor inhibitors.^{13,16}

Optical coherence tomography angiography (OCTA) enables high-resolution imaging of the microvascular structure of the retina. The vascular pattern is detected based on changes in reflectance patterns of repeated B-scans.¹⁷ In contrast to FA, dye injection is not necessary.¹⁸ In addition to its use to image the more common retinal diseases such as diabetic retinopathy, central serous retinopathy, and age-related macular degeneration,^{18,19} OCTA has also been established as an imaging technique for RHs in VHL.^{20–23} It can be used to detect RHs, to evaluate treatment effects, and to monitor progression of the RHs.^{21,22} Nevertheless, there are limiting factors that affect OCTA measurements, such as the reduced angle of view and possible shadowing artifacts.^{20–23}

Although OCTA was initially limited to the central retina, today widefield images can be obtained, as well.²⁴ For example, in diabetic retinopathy, widefield OCTA (wOCTA) has been reported to have a better detection rate of retinal vascular proliferations than ophthalmoscopy alone.²⁴ This might also apply to the detection of RHs in VHL. Early treatment

improves the prognosis for smaller RHs but requires accurate localization. Unfortunately, very small RHs can easily be overlooked.¹² Therefore, the primary aim of our study was to compare the detection rate of RHs in VHL via wOCTA with the detection rate of RHs via ophthalmoscopy. In a second step, we aimed to compare the detection rates of RHs for OCTA, ophthalmoscopy, and FA in cases where FA was performed for crucial therapeutic decisions.

Methods

Study Design

This was a prospective, single-center, cross-sectional study approved by the institutional Ethics Committee of the University of Freiburg, Freiburg, Germany (ID number 360/19), and it adhered to the tenets of the Declaration of Helsinki. Signed informed consent was obtained from all participants.

Study Population

A total of 50 consecutive patients with *VHL*-gene mutation confirmed or clinically suspected VHL due to VHL in their family history or the presence of typical VHL tumors were routinely examined at the Eye Center, Faculty of Medicine, University Freiburg, Germany, between May 2020 and October 2020. Patient characteristics such as sex, date of birth, and detected *VHL*-gene mutation were documented after clinical examination.

Ophthalmological Examination

All patients underwent the following examinations in the listed order. First, autorefractometry and best-corrected visual acuity evaluations were performed by medical technical assistants. After dilation with tropicamide 1% eye drops, ultra-widefield photographs (P200DTx/A10650; Optos, Dunfermline, UK) were obtained.

Optical Coherence Tomography Angiography

OCTA images were recorded with the commercially available ZEISS PLEX Elite 9000 OCTA system (Carl Zeiss Meditec, Dublin, CA), which uses full-spectrum swept-source OCT with a light-source wavelength of 1050 nm, an A-scan rate of 100,000 A-scans per second, and an A-scan depth of 3.0 mm in tissue (1536 pixels). The OCTA system utilizes the optical microangiography algorithm to decorrelate signal detection. A real-time image-stabilizer (FastTrac; Carl Zeiss

Meditec) ensures a minimum of movement artifacts. The built-in montage software tool was used to create wOCTA images using five $12 \times 12\text{-mm}^2$ scans distributed over the retinal surface. If an area in the wOCTA image was considered suspect, an additional $3 \times 3\text{-mm}^2$ scan of this area was performed. Results were interpreted by two investigators (MD, MR) experienced with VHL and OCTA imaging.

Slit-Lamp Examination With Ophthalmoscopy

Biomicroscopy of the anterior segment and fundus examination were performed by doctors familiar with VHL (AG, FB, MF, SJL, VG, YL). Three different Volk lenses (SuperField; digital widefield 90D, 20D, or Pan Retinol 2.2; and 3-Mirror; Volk Optical, Mentor, OH) were used for the ophthalmoscopy. Ultra-widefield photography was obtained to assist with orientation during ophthalmoscopy.

Fluorescein Angiography

In the clinical practice of the Eye Center, Faculty of Medicine, University Freiburg, Germany, FA is performed in VHL patients when ophthalmoscopy is not sufficient to make a treatment decision. Therefore, in this study, we performed FA only in cases where the treatment decision was not clear after ophthalmoscopy and OCTA. FA was performed with the SPECTRALIS Ultra-Widefield Imaging Module (Heidelberg Engineering, Heidelberg, Germany). Obtained images were interpreted independently by experienced FA specialists (HA, CL).

Inclusion and Exclusion Criteria

Only patients with confirmed *VHL*-gene mutation or clinically expected VHL were included. According to their medical history, patients with systemic disease such as diabetes mellitus or cardiovascular diseases were not included. Furthermore, patients with other retinal diseases or eyes with silicon oil tamponade were excluded. Eyes revealing media opacities, such as an advanced cataract, were also excluded due to reduced OCTA signal strength, as well as eyes with a refractive error exceeding -7 diopters (D) due to their negative impact on image quality in the periphery. Only images with signal strength equal to or greater than 7 were included. If the image quality was not sufficient due to other artifacts, such as motion artifacts, then the images were excluded from the study ex post.

Documentation of the Detected RHs

Localizations of detected RHs were plotted on retinal maps independently based on investigator

group (ophthalmoscopy, OCTA, FA). Additional high-resolution photography of the detected RHs with an FF450 fundus camera (Carl Zeiss Meditec) was performed. Only tumors that were detected by two independent examiners were included in the analysis. If there was disagreement, an attempt was made to find a common consensus between the two examiners. If a common consensus could not be found, the tumor was declared to be not reliably detected (“suspected diagnosis”) and was excluded from the data analysis.

Quantitative Measurement of the Percentage of the Retina Examined

Although only about 40% to 50% of the entire retina can be examined with wOCTA, slit-lamp examination with ophthalmoscopy and performing FA offer the possibility of examining the entire retina. A quantitative measurement of the percentage of the retina examined with the individual examination methods was not performed.

Tumor Size Measurement

The tumor size was estimated via ophthalmoscopy in relation to the optic disc size as follows: <0.25 disc diameter (DD), 0.25 to 1 DD, 1 to 2 DD, and >2 DD.²²

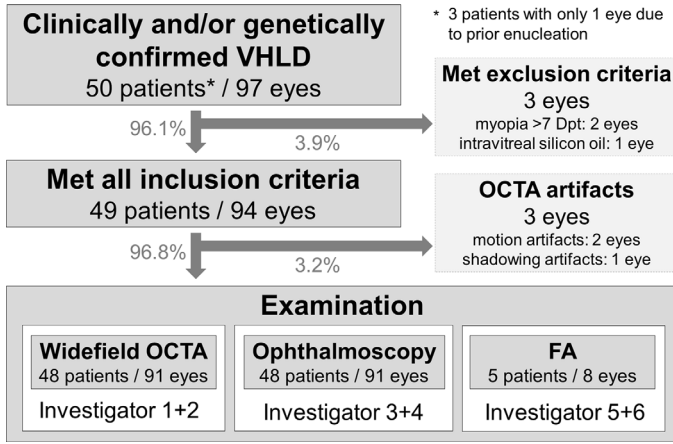
Statistical Analysis

SPSS Statistics 20.0 (IBM, Chicago, IL) was used for statistical analysis. For the descriptive data analysis, mean \pm standard deviation (SD), as well as median and minimal and maximal values (range), were calculated. The total amount of detected RHs was combined from the results of all three examination techniques (ophthalmoscopy, wOCTA, and FA). This reference value was used to calculate the individual detection rate of each examination technique. Detection rates were obtained using SPSS Statistics 20.0 cross-tabulation analysis. For analysis of statistical significance, the χ^2 test was used; $P < 0.05$ was considered statistically significant. In order to do justice to the situation that the current wOCTAs can only image 40% to 50% of the entire retina, the analyses were performed twice: first, in relation to the entire retina, and, second, in relation to only the retinal area that can be imaged by wOCTA.

Results

Patient Characteristics

Data for 50 consecutive patients (97 eyes) were obtained (Fig. 1). In three patients, data were available



for only one eye due to prior enucleation of the fellow eye because of complications after treatment of RHs. Thirty-two patients were female (64%), and 18 patients were male (36%). Mean age at study inclusion was 38.8 ± 18.0 years (median, 38.1; range, 8.1–70.7). *VHL*-gene mutation was confirmed in 40 patients. None of the patients presented concomitant maculopathy or retinopathy. Two eyes of one patient were excluded due to high myopia and one eye of another patient due to intravitreal silicon oil after previous vitrectomy due to retinal detachment. OCTA images showed motion artifacts due to nystagmus in both eyes of one patient and shadowing artifacts due to a dense cataract in one eye of another patient. These eyes were also excluded from further analysis due to insufficient image quality. Therefore, in total, 91 eyes of 48 patients could be included in the data analysis. FA was performed in eight

Figure 1. Flow chart of patients screened and included in the study. Data regarding the patient inclusion and exclusion criteria and the screening methods performed are shown.

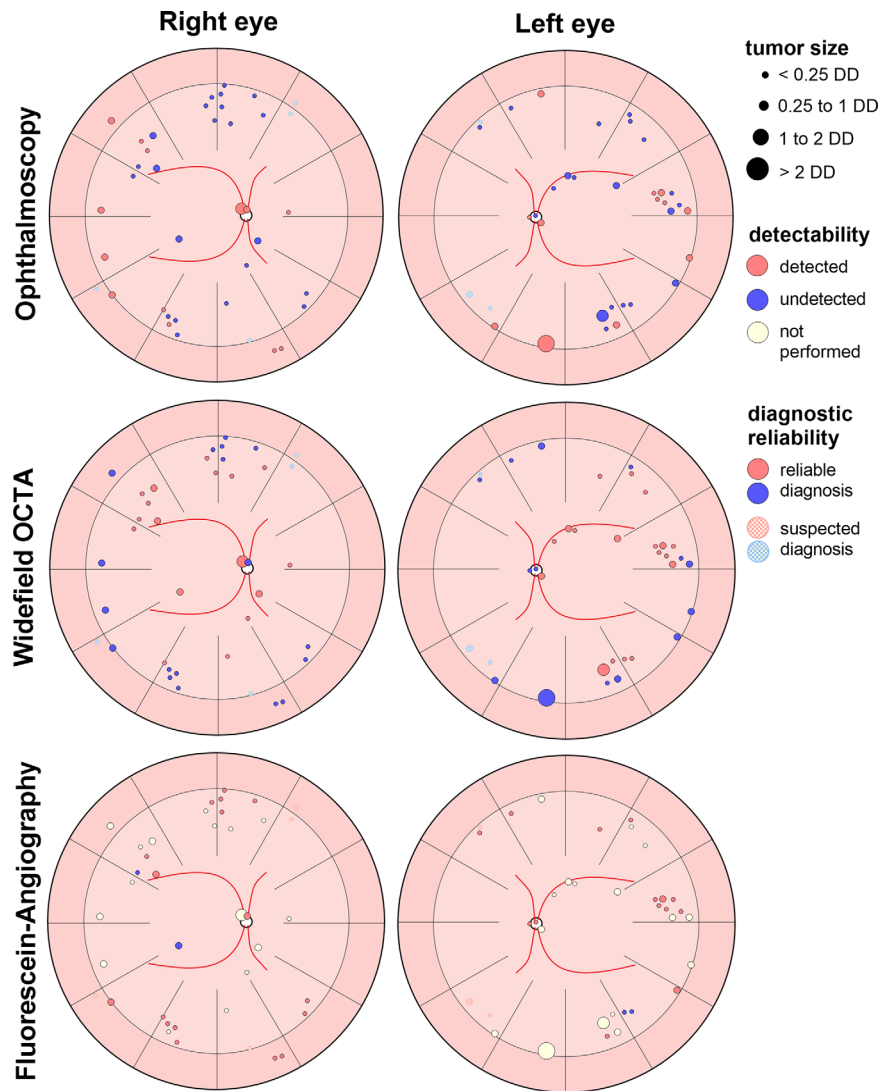


Figure 2. Localization, clinically estimated tumor size, detectability, and diagnostic reliability of the detected 67 retinal hemangioblastomas. Results of all three screening methods—ophthalmoscopy, wOCTA, and FA—are given separately. The tumor sizes were determined on the basis of vertical optic disc diameter (DD).

Table 1. Number of Reliably Detected RHs in the Whole Retina by Screening Method

	Detected RHs, <i>n</i> (%)	
	91 Eyes Examined With Osc and OCTA	8 Eyes Examined With Osc, OCTA, and FA
Total number of detected RHs	67 (100)	35 (100)
Osc	25 (37.3)	11 (31.4)
Detected in Osc but not in OCTA	15 (22.4)	6 (17.1)
Detected in Osc but not in FA	—	0 (0)
OCTA	35 (52.2)	12 (34.3)
Detected in OCTA but not in Osc	25 (37.3)	6 (17.1)
Detected in OCTA but not in FA	—	4 (11.4)
FA	—	31 (88.6)
Detected in FA but not in Osc	—	20 (57.1)
Detected in FA but not in OCTA	—	23 (65.7)

FA revealed seven peripherally located spots that were defined as suspected tumors by only one of the two investigators. A clear conclusive statement about the actual presence of a tumor could not be made for these spots; therefore, these spots are not listed in the table. Osc, ophthalmoscopy.

Table 2. Number of Reliably Detected RHs Within the Retinal Area Covered by OCTA by Screening Method

	Detected RHs, <i>n</i> (%)	
	91 Eyes Examined With Osc and OCTA	8 Eyes Examined With Osc, OCTA, and FA
Total number of detected RHs	38 (100)	15 (100)
Osc	12 (31.6)	7 (46.7)
Detected in Osc but not in OCTA	2 (5.3)	2 (13.3)
Detected in Osc but not in FA	—	0 (0)
OCTA	35 (92.1)	12 (80)
Detected in OCTA but not in Osc	25 (65.7)	5 (33.3)
Detected in OCTA but not in FA	—	4 (26.7)
FA	—	11 (73.3)
Detected in FA but not in Osc	—	4 (26.7)
Detected in FA but not in OCTA	—	3 (20)

FA revealed seven peripherally located spots that were defined as suspected tumors by only one of the two investigators. A clear conclusive statement about the actual presence of a tumor could not be made for these spots; therefore, these spots are not listed in the table.

eyes of five patients. A sufficient treatment decision was not possible after ophthalmoscopy and OCTA for five patients (eight eyes); therefore, FA was performed in these patients.

Retinal Hemangioblastoma Detection

A total of 67 RHs in 91 eyes (48 patients) were detected (mean, 0.74 ± 1.59 RH per eye; median, 0; range, 0–9): 35 in the right eye and 32 in the left eye. Additionally, seven RHs were suspected by only one of the two investigators interpreting FA images and therefore were not included in the further analysis as RHs.

Five RHs were located peripapillary (7.5%) and 62 RHs were located peripherally (92.5%). Of the peripherally located RHs, 35 were primary tumors (52.2%); 27 peripherally located RHs were located in pretreated areas (40.3%) and therefore were considered as recurrent RHs. The tumor sizes of 44 RHs were <0.25 DD (65.7%); of 20 RHs, 0.25 to 1 DD (29.9%); of two RHs, 1 to 2 DD (3%); and of one RH, >2 DD (1.5%). [Figure 2](#) illustrates which RH was detected with which screening method. The absolute number of RHs detected using each of the three screening methods is presented in two ways: [Table 1](#) shows the counts for the entire retina, and [Table 2](#) focuses only on the area

Table 3. Screening Method Detection Rates for the Whole Retina

	Detected RHs, <i>n</i>	Detection Rate, %	<i>P</i>
91 eyes examined with Osc and OCTA	67		0.082
Osc	25	37.3	
OCTA	35	52.2	
8 eyes examined with Osc, OCTA, and FA	35		<0.0001
Osc	11	31.4	
OCTA	12	34.3	
FA*	31	88.6	

*Seven peripherally located spots were defined as suspected tumors by only one of the two investigators. A clear conclusive statement about the actual presence of a tumor could not be made for these spots.

Table 4. Screening Method Detection Rates Within the Retinal Area Covered by OCTA

	Detected RHs, <i>n</i>	Detection Rate, %	<i>P</i>
91 eyes examined with Osc and OCTA	38		<0.0001
Osc	12	31.6	
OCTA	35	92.1	
8 eyes examined with Osc, OCTA, and FA	15		0.12
Osc	7	46.7	
OCTA	12	80.0	
FA	11	73.3	

covered by wOCTA. The detection rates derived from these counts are summarized in [Tables 3](#) and [4](#), respectively.

Reasons for Undetected RHs

Twenty-five of the 35 RHs being detected by OCTA (71.4%) were missed by ophthalmoscopy alone. The probable reasons for non-detection were masking by the background color of the choroid ($n = 5$), small tumor size ($n = 13$), masking by a bright fundus reflex ($n = 2$), and masking of relapsing RHs by surrounding retinal scars ($n = 5$). Examples of each of these reasons are illustrated in [Figure 3](#). Four RHs masked by the background color of the choroid, bright fundus reflex, or surrounding retinal scars also had a tumor size of <0.25 DD. Therefore, 17 of the 25 undetected RHs via ophthalmoscopy had a tumor size of <0.25 DD; seven RHs, 0.25 to 1 DD; and one RH, 1 to 2 DD. The latter was a flat tumor masked by an intensely pigmented scar area. Because wOCTA is able to image just around 50% of the whole retina, of the total detected 67 RHs, 29 RHs could not be detected via OCTA due to peripheral location (43.3%). All three centrally located RHs that were missed by wOCTA were located peripapillary. Comparing OCTA and FA, only eight of the 15 RHs located in the retinal area (53.3%) that were able

to be examined via wOCTA were detected by both OCTA and FA. Of the seven RHs detected by either OCTA or FA, the four RHs detected only by OCTA were located in the area of the great arches, whereas the three RHs detected only by FA were located peripapillary. Examples of RHs detected only by OCTA or by FA, as well as an example of an RH that was detected by both OCTA and FA, are illustrated in [Figure 4](#).

Discussion

Patients with VHL must be screened for RHs throughout their lives, and very early treatment of the tumors improves the clinical outcome. Our results show that wOCTA may be a useful additional tool to improve this screening, whereas ophthalmoscopy alone seems to be less sensitive for very small RHs. FA was capable of finding more RHs than ophthalmoscopy and OCTA. It has been previously reported that FA is more sensitive in detecting RHs than ophthalmoscopy.¹⁴ However, the rate of RHs detected by OCTA was unclear. Therefore, the aim of our study was to compare the detection rate of RHs in VHL via wOCTA with the detection rate of RHs via the current standard of clinical VHL screening.

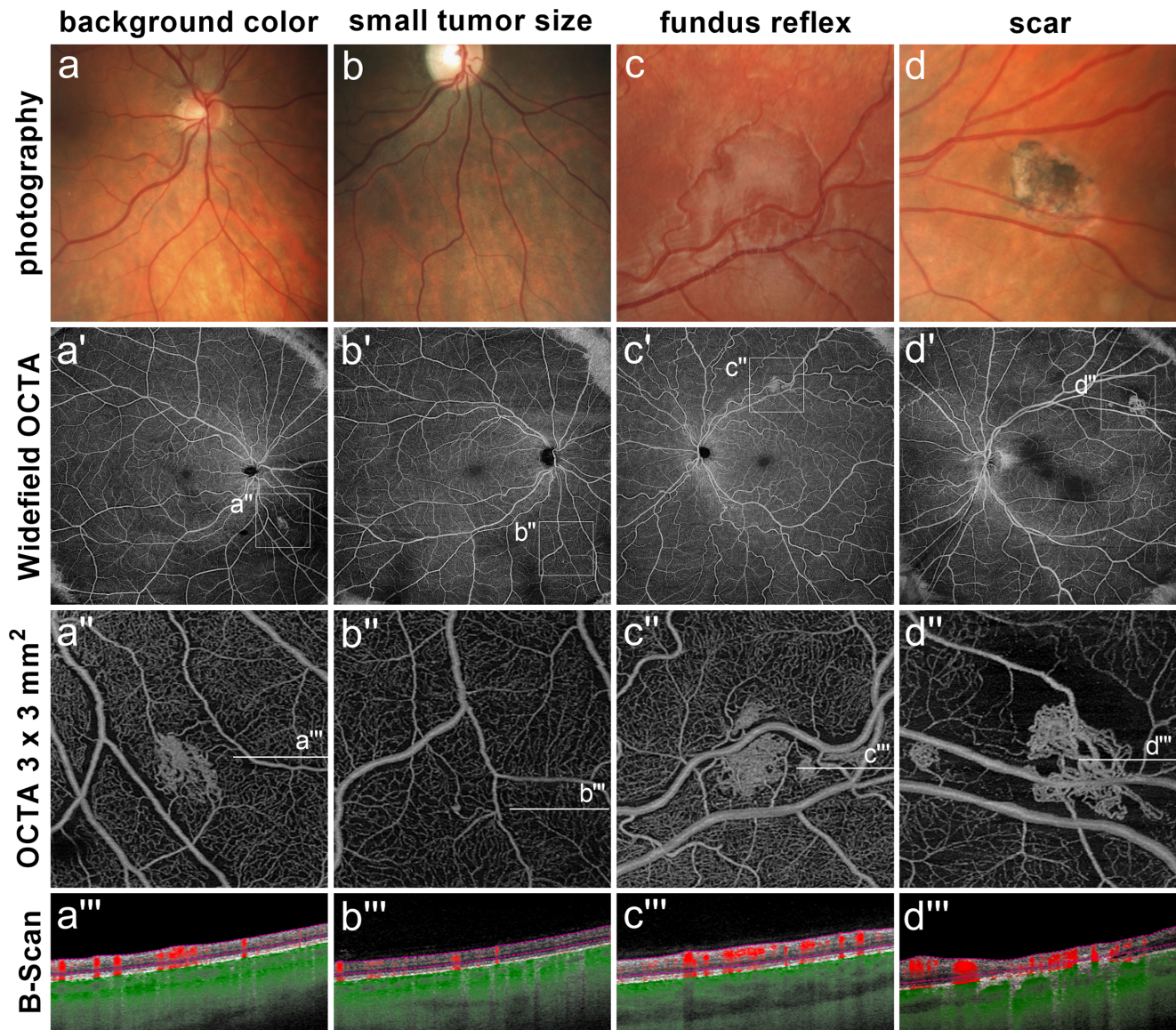


Figure 3. RHs overlooked by photography (a–d), wOCTA (a'–d'), OCTA 3 × 3-mm² scans (a''–d''), and OCTA B-scans (a'''–d''') are shown. In case (a), the reddish background of the choroid masked the reddish tumor. Vascular imaging (a', a'') by OCTA showed the full extent of the tumor. Case (b) shows a very small RH, which was more clearly visible in OCTA analysis (b', b''). Case (c) shows a bright retinal reflex in an 18-year-old patient. OCTA revealed the RH that could not be seen due to the reflex. Case (d) shows a relapse of an RH in a retinal scar. Due to the dark pigmentation of the pretreated area the RH was not clearly visible upon clinical examination. OCTA revealed the relapse of the tumor, as well as an additional primary tumor being hidden in the photograph due to the reddish background of the choroid.

Comparison of Detection Rates With the Literature

Overall, we detected a mean of 0.74 ± 1.59 RH per eye. This rate is almost twice as high as in our previous studies (mean 0.42 ± 0.89 RH per eye),²² a finding that is mainly explained by the fact that in our previous study only ophthalmoscopy was used for primary screening, so some RHs might have been overlooked.

Ophthalmoscopy Compared to wOCTA

Comparing ophthalmoscopy with wOCTA, ophthalmoscopy overlooked 25 RHs that were detected by wOCTA. Fifteen RHs were detected by ophthalmoscopy but were missed by wOCTA; furthermore, it should be mentioned, that only two of these RHs were located within the imaging range of wOCTA. In line with these results, a high detection rate of vascular lesions by OCTA has been described in the

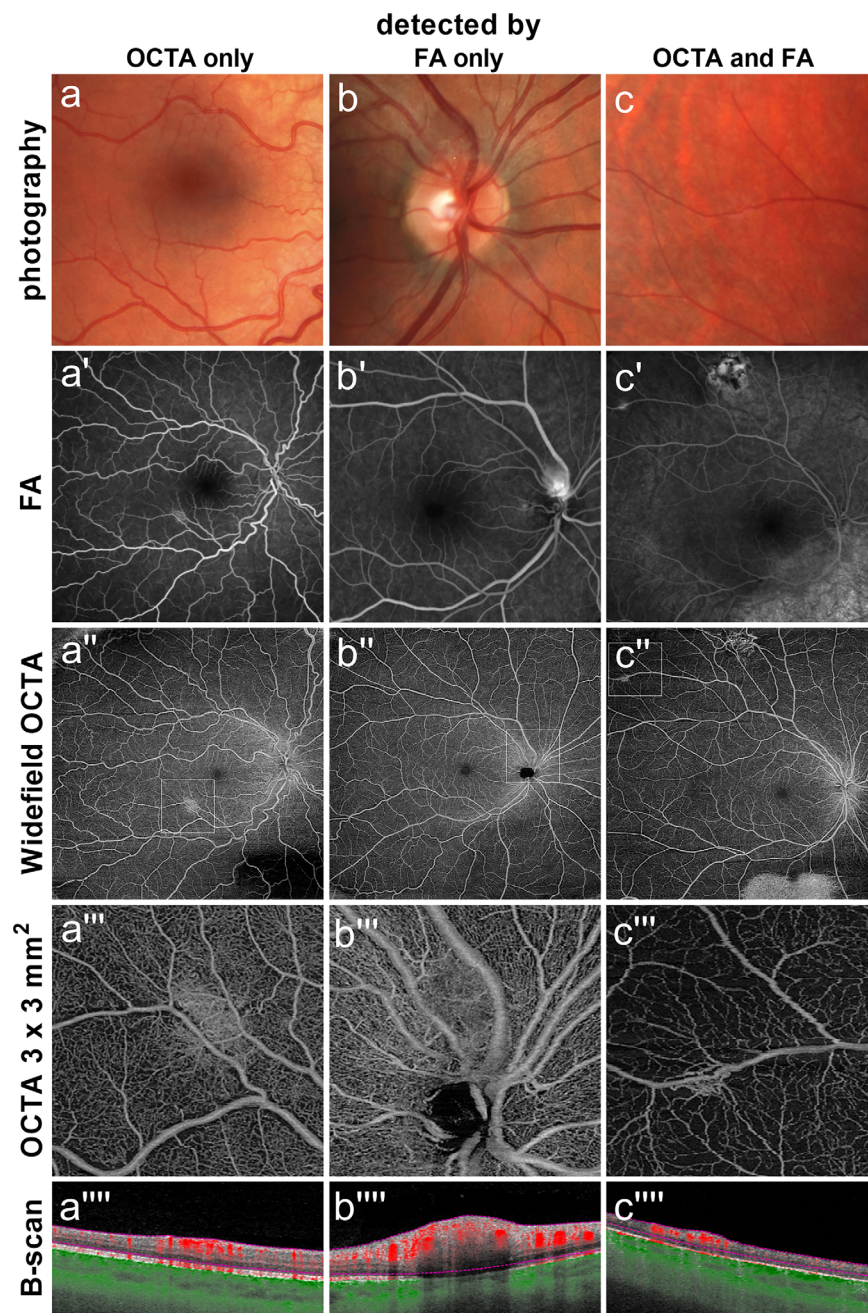


Figure 4. RHs overlooked or detected by OCTA and FA. Photography (a–c), FA (a'–c'), wOCTA (a''–c''), OCTA $3 \times 3\text{-mm}^2$ scan (a'''–c'''), and OCTA B-scan (a''''–c''') results are shown for each RH. In case (a), FA failed to detect two small RHs due to missing leakage, whereas OCTA was able to detect both microangiomas. Case (b) shows a peripapillary RH that was detectable with ophthalmoscopy and FA, but wOCTA and $3 \times 3\text{-mm}^2$ scans failed to diagnosis it due to the partial fibrosis of the RH and the high vascular peripapillary density of the peripapillary area in the wOCTA. The presence of the tumor could only be guessed at in the OCTA B-scan, which showed thickening of the retina and increased blood flow in the affected area. Case (c) illustrates an RH that was detected with both FA and OCTA.

literature,^{18,20,24,25} as well as a higher detection rate in proliferative diabetic retinopathy compared to clinical examination alone.²⁴ Furthermore, it has been shown that wOCTA can detect more vascular lesions (intraretinal microvascular abnormalities, neovascularization elsewhere, and neovascularization of the optic disc) than ultra-widefield color fundus photography.²⁵

For the examination of RHs, important drawbacks of wOCTA include long examination times and limited fields of view.^{21,22} Furthermore, the interpretation and diagnostic value of peripheral OCTA scans may be impaired due to artifacts.²⁶ In our study, three eyes had to be excluded due to artifacts, and 29 RHs were out of range for the wOCTA. Therefore, artifacts and

limitations in imaging the peripheral retina may impair the use of wOCTA alone for screening of patients with VHL.

FA Compared to Ophthalmoscopy and wOCTA

Thus far, FA has been considered the gold standard, and OCTA is usually compared to FA in diagnostic accuracy.²⁷ OCTA cannot detect leakage, which may be a disadvantage.²⁷ On the other hand, excessive dye extravasation can inhibit visualization of the vascular structure.²¹ In our study, in the cases examined using the two modalities of wOCTA and FA, only eight of the 15 RHs located in the area of the wOCTA were detected with both methods (53.3%). Four RHs were only detected by wOCTA and three RHs only by FA. This result also suggests that neither wOCTA nor FA alone may be able to detect all RHs in patients with VHL. Because all RHs overlooked by OCTA are located peripapillary, an additional 3 × 3-mm² OCTA scan of the optic nerve should be considered in order to reduce the number of overlooked RHs.

Overall Detection Rate

With regard to overall detection rates (Table 3), the wOCTA rate ranges from 34.3% to 52.2%, depending on the availability of FA comparison. FA showed a detection rate of 88.6%, and ophthalmoscopy showed a detection rate of 31.4% to 37.3%. When regarding only the area of the retina covered by wOCTA (Table 4), the detection rate of wOCTA ranged from 80% to 92.1%, which is higher than the detection rates of ophthalmoscopy and FA (31.6%–46.7% and 73.3%, respectively). This finding demonstrates that the main disadvantage of wOCTA in VHL screening is the limited angle of view when examining the retinal periphery. Studies investigating the sensitivity and specificity of OCTA and FA in other retinal diseases have demonstrated a high accuracy of OCTA when compared to FA.²⁸

Reasons for Undetected RHs

Difficulties with RH diagnosis due to abnormal coloration and non-visible vasculature have been described before, along with the potential for OCTA to aid in establishing the diagnosis.²⁹ Furthermore, the ability to detect blood flow in lesions being obscured by retinal scars enables OCTA to detect RHs that are not easily identifiable by ophthalmoscopy.^{20,22} In line with these reports, 12 of the 25 RHs overlooked by ophthalmoscopy in our study were not diagnosed due to the background color of the choroid leading to masking by a bright fundus reflex or masking by surrounding retinal scars. However, it is not surprising that the main reason for overlooking RHs is the small tumor size, with one study reporting more than 50% (13 of 25) RHs being overlooked.¹² The clear advantage of OCTA is that even very small RHs can be diagnosed reliably using this technology,²² and therapy can be initiated at a very early stage if necessary, reducing the risk of side effects associated with growing RHs and the risk of loss of vision.

Limitations of our study include the small number of patients, especially in the comparison of ophthalmoscopy, wOCTA, and FA, as FA was performed in only eight eyes. There is a possible bias because FA was only performed when needed for therapeutic decision making despite having OCTA information. We therefore might have overestimated the rate of missed RHs by ophthalmoscopy and wOCTA. In the eight eyes that were screened with all three methods, it was found that some RHs were missed in the periphery by ophthalmoscopy alone (16 more RHs were detected with FA in the area not covered by wOCTA compared to ophthalmoscopy). Because 83 eyes were not examined with FA, the actual number of RHs is most likely higher than 67. However, a massively higher number of RHs cannot be assumed, as FA was performed only in severely diseased eyes with a high probability for RHs. Accordingly, the 83 eyes not examined by FA may rather represent eyes with a lower probability of RHs. Another limitation is, that quantitative measurement of the percentage of the retina examined with the individual examination methods was not performed. Therefore, an exact comparison of the detection rates of the different examination methods is not entirely possible.

Limitations of the Study

Because there exists no gold standard for the detection of RHs, the sensitivity and specificity of the different screening methods cannot be determined. Therefore, we decided to use the detection rate as the unit of measurement. A large prospective trial with ophthalmoscopy, OCTA, and FA in every patient is needed to evaluate whether the rates of missed RHs by ophthalmoscopy and OCTA are high enough to justify routine FA despite its being an invasive procedure.

Conclusions

In conclusion, wOCTA may be a useful additional tool to improve the screening of patients with VHL.

The high number of overlooked RHs suggests that ophthalmoscopy alone is less sensitive for small RHs in VHL. In all cases with FA, even more RHs were found than in ophthalmoscopy and OCTA. Future prospective studies are needed to determine whether a combination of ophthalmoscopy and OCTA is sufficient for screening in VHL or whether FA should be performed routinely.

Acknowledgments

The authors thank the participants of the study.

Supported by the Verein VHL (von Hippel–Lindau) betroffener Familien e.V. and by the Gabriele Lederle-Stiftung. We thank these organizations very much for their support.

Disclosure: **S.J. Lang**, None; **M. Dreesbach**, None; **Y. Laich**, None; **A. Glatz**, None; **D. Boehringer**, None; **V. Grewing**, None; **M. Fritz**, None; **F. Bucher**, None; **W.A. Lagrèze**, None; **P.M. Maloca**, Roche (C), Zeiss (C); **T. Reinhard**, None; **C. Lange**, None; **H. Agostini**, None; **M. Reich**, None

References

1. Maher ER, Iselius L, Yates JR, et al. Von Hippel-Lindau disease: a genetic study. *J Med Genet*. 1991;28(7):443–447.
2. Weisbrod AB, Kitano M, Thomas F, et al. Assessment of tumor growth in pancreatic neuroendocrine tumors in von Hippel Lindau syndrome. *J Am Coll Surg*. 2014;218(2):163–169.
3. Conway JE, Chou D, Clatterbuck RE, Brem H, Long DM, Rigamonti D. Hemangioblastomas of the central nervous system in von Hippel-Lindau syndrome and sporadic disease. *Neurosurgery*. 2001;48(1):55–62; discussion 62–63.
4. Padhi S, Sarangi R, Challa S, Bussary P, Panigrahi MK, Purohit AK. A 10-year retrospective study of hemangioblastomas of the central nervous system with reference to von Hippel–Lindau (VHL) disease. *J Clin Neurosci*. 2011;18(7):939–944.
5. Wong WT, Agrón E, Coleman HR, et al. Clinical characterization of retinal capillary hemangioblastomas in a large population of patients with von Hippel–Lindau disease. *Ophthalmology*. 2008;115(1):181–188.
6. Green JS, Bowmer MI, Johnson GJ. Von Hippel-Lindau disease in a Newfoundland kindred. *CMAJ*. 1986;134(2):133–138, 146.
7. Horton WA, Wong V, Eldridge R. Von Hippel-Lindau disease: clinical and pathological manifestations in nine families with 50 affected members. *Arch Intern Med*. 1976;136(7):769–777.
8. Reich M, Jaegle S, Neumann-Haefelin E, et al. Genotype–phenotype correlation in von Hippel-Lindau disease. *Acta Ophthalmologica*. 2021;99(8):e1492–e1500.
9. Launbjerg K, Bache I, Galanakis M, Bisgaard ML, Binderup MLM. von Hippel-Lindau development in children and adolescents. *Am J Med Genet A*. 2017;173(9):2381–2394.
10. Grossniklaus HE, Thomas JW, Vigneswaran N, Jarrett WH. Retinal hemangioblastoma. A histologic, immunohistochemical, and ultrastructural evaluation. *Ophthalmology*. 1992;99(1):140–145.
11. Toy BC, Agrón E, Nigam D, Chew EY, Wong WT. Longitudinal analysis of retinal hemangioblastomatosis and visual function in ocular von Hippel-Lindau disease. *Ophthalmology*. 2012;119(12):2622–2630.
12. Schmidt D, Agostini HT. [Retinal angiomatosis—an ophthalmological challenge]. *Klin Monbl Augenheilkd*. 2007;224(12):905–921.
13. Junker B, Schmidt D, Agostini HT. [Retinal angiomatosis—ocular manifestation of von Hippel-Lindau disease]. *Ophthalmologie*. 2007;104(2):107–113.
14. Chen X, Sanfilippo CJ, Nagiel A, et al. Early detection of retinal hemangioblastomas in von Hippel-Lindau disease using ultra-widefield fluorescein angiography. *Retina*. 2018;38(4):748–754.
15. Kornblau IS, El-Annan JF. Adverse reactions to fluorescein angiography: a comprehensive review of the literature. *Surv Ophthalmol*. 2019;64(5):679–693.
16. Kim H, Yi JH, Kwon HJ, Lee CS, Lee SC. Therapeutic outcomes of retinal hemangioblastomas. *Retina*. 2014;34(12):2479–2486.
17. Kim DY, Fingler J, Zawadzki RJ, et al. Optical imaging of the chorioretinal vasculature in the living human eye. *Proc Natl Acad Sci USA*. 2013;110(35):14354–14359.
18. Lang GE, Enders C, Werner JU. [New possibilities in retinal diagnostics using OCT angiography]. *Klin Monbl Augenheilkd*. 2016;233(5):613–621.
19. Cakir B, Reich M, Lang SJ, et al. [Possibilities and limitations of OCT-angiography in patients with central serous chorioretinopathy]. *Klin Monbl Augenheilkd*. 2017;234(9):1161–1168.
20. Lang SJ, Cakir B, Evers C, Ludwig F, Lange CAK, Agostini HT. Value of optical coherence tomography angiography imaging in diagnosis and treatment of hemangioblastomas in von Hippel-Lindau

- disease. *Ophthalmic Surg Lasers Imaging Retina*. 2016;47(10):935–946.
21. Lang SJ, Evers C, Cakir B, Ludwig F, Lange C, Agostini H. [Optical coherence tomography angiography in diagnosis and post-treatment assessment of hemangioblastomas in Hippel-Lindau disease]. *Klin Monbl Augenheilkd*. 2017; 234(9):1146–1153.
 22. Reich M, Glatz A, Boehringer D, et al. Comparison of current optical coherence tomography angiography methods in imaging retinal hemangioblastomas. *Transl Vis Sci Technol*. 2020;9(8):12.
 23. Reich M, Boehringer D, Rothaus K, et al. Swept-source optical coherence tomography angiography alleviates shadowing artifacts caused by subretinal fluid. *Int Ophthalmol*. 2020;40(8):2007–2016.
 24. Khalid H, Schwartz R, Nicholson L, et al. Wide-field optical coherence tomography angiography for early detection and objective evaluation of proliferative diabetic retinopathy. *Br J Ophthalmol*. 2021;105(1):118–123.
 25. Cui Y, Zhu Y, Wang JC, et al. Comparison of widefield swept-source optical coherence tomography angiography with ultra-widefield colour fundus photography and fluorescein angiography for detection of lesions in diabetic retinopathy. *Br J Ophthalmol*. 2021;105(4):577–581.
 26. De Pretto LR, Moulton EM, Alibhai AY, et al. Controlling for artifacts in widefield optical coherence tomography angiography measurements of non-perfusion area. *Sci Rep*. 2019;9(1):9096.
 27. Perrott-Reynolds R, Cann R, Cronbach N, et al. The diagnostic accuracy of OCT angiography in naive and treated neovascular age-related macular degeneration: a review. *Eye (Lond)*. 2019;33(2):274–282.
 28. Gan Y, Zhang X, Su Y, Shen M, Peng Y, Wen F. OCTA versus dye angiography for the diagnosis and evaluation of neovascularisation in punctate inner choroidopathy. *Br J Ophthalmol*. 2022;106(4):547–552.
 29. Custo Greig EP, Duker JS. Retinal hemangioblastoma vascular detail elucidated on swept source optical coherence tomography angiography. *Am J Ophthalmol Case Rep*. 2020;21:101005.